

# *In vivo* biological evaluation of AVINENT dental implants

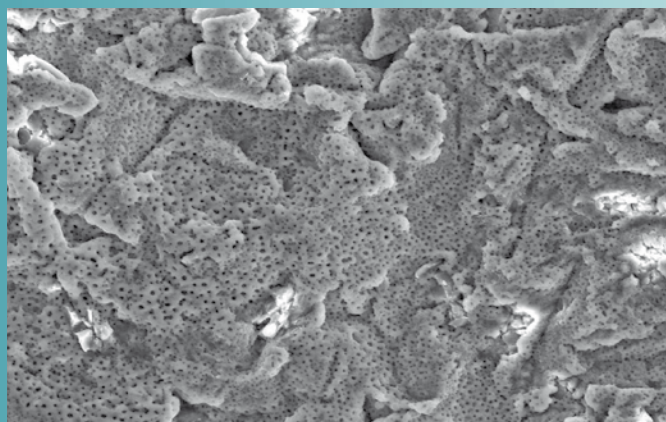
## PURPOSE

To evaluate the *in vivo* short and medium-term performance of the AVINENT BIOMIMETIC ADVANCED SURFACE treatment by implantation in pigs.

## MATERIALS AND METHODS

### **Animal Model**

A total of 6 pigs were used from an experimental animal breeding centre. The use of the animals was authorised by the Universitat Autònoma de Barcelona Ethics Committee.



**Figure 1.** Appearance of the AVINENT implants surface

Document prepared by the **scientific committee of AVINENT Implant System S.L.** <sup>(1)</sup> with the collaboration of **CREB** (Centre de Recerca en Enginyeria Biomèdica) <sup>(2)</sup> and the **Skeletal and muscular pathology research group that belongs to UB** (Universitat de Barcelona) <sup>(3)</sup>.

<sup>(1)</sup> **Scientific committee of AVINENT Implant System S.L.**, A. Cortina, C. Vendrell, E. Falcó, J. Serra

<sup>(2)</sup> **CREB:** A. Mestre

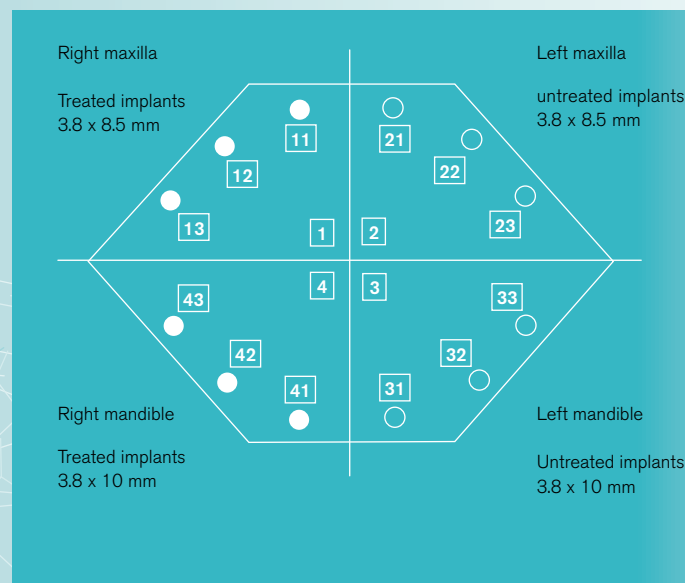
<sup>(3)</sup> **Universidad de Barcelona:** M<sup>a</sup> C. Manzanares, I. Valdivia

## Implants

2 types of implants were used:

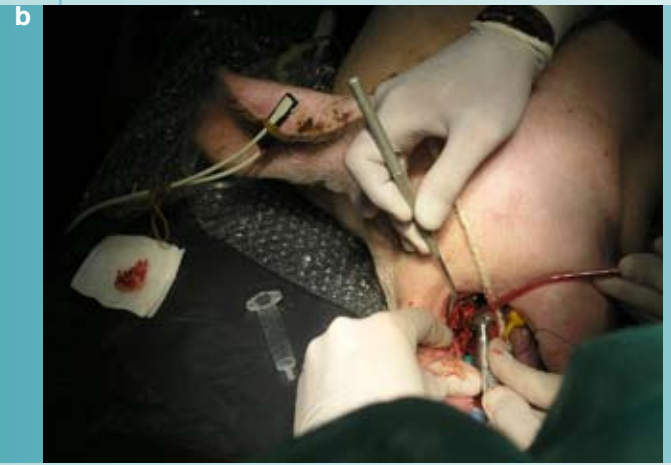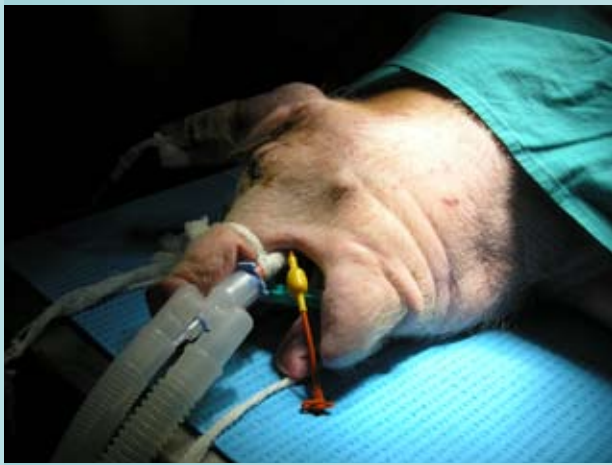- AVINENT Implants. Dental implants made with the Ti6A14V ELI alloy and the Biomimetic Advanced Surface (BAS) surface treatment, which is obtained using a physical and chemical treatment and the incorporation of calcium and phosphorus ions during the process. The result of the combination of these processes is characterised by the macro-roughness and micro-porosity (fig. 1).
- Mechanical implants without surface treatment. Made with Ti6A14V ELI alloy and geometrically identical to the AVINENT implants.

3.8 mm diameter by 8.5 mm long self-tapping endosseous implants were used for the superior maxillary and 10 mm long implants for the mandible. 12 implants were placed in each animal (6 surface-treated and 6 untreated). The distribution of the implants within the mouth is shown in figure 2.



**Figure 2.** Schematic distribution of the implants in the mouth.

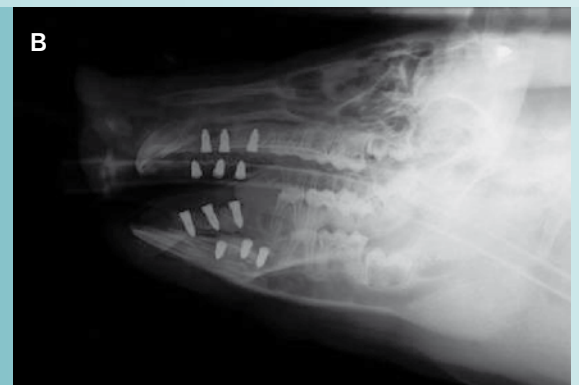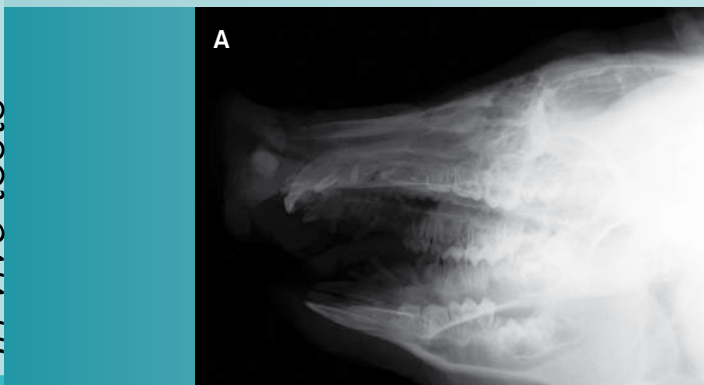
# *In vivo* biological evaluation of AVINENT dental implants



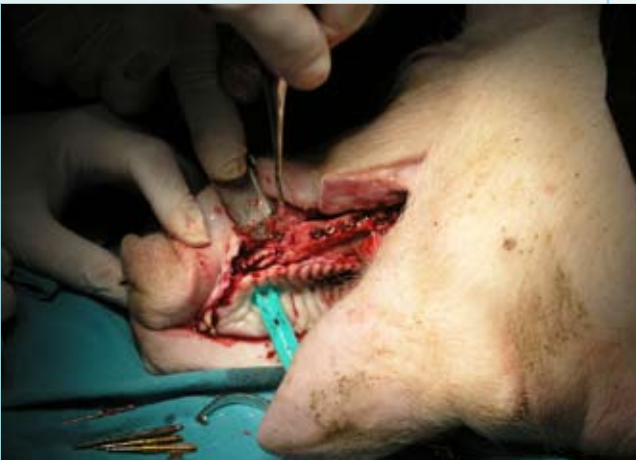## **Surgical Technique**

The surgical interventions were carried out at the Veterinary University of the Universitat Autònoma de Barcelona. The preparation, care and euthanasia of the animals was carried out by a team of the university's veterinarians. The placement of the implants was carried out by a team of 6 dentists and 2 nurses. For intervention of each of the animals, the dentists were distributed in different working pairs.

Radiographs were taken before and after intervention (fig. 4) and immediately after the animals were euthanised.



**Figure 4.** Radiographs of the cranium of one of the pigs (A) before implantation and (B) after implantation.



**Figure 3.** Series of images (a, b, c) of the placement of the implants in the maxilla of one of the pigs.

### **Sample Processing for Histomorphology and Results.**

#### ***Euthanasia timing***

3 pigs (A, B and C) were euthanised at 45 days from the intervention and the remaining 3 (D, E and F) at 90 days.

#### ***Preparation of the histological sections***

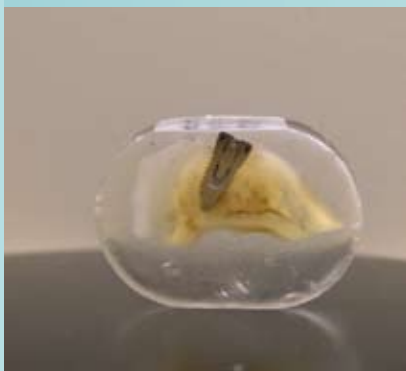After the extraction of the maxillae, the histological sections were prepared as described below:

- a) Formol-fixation: first, the extracted maxillae were fixed by immersion in 10% formol.
- b) Obtaining the histological sections. The implants were individually separated from each maxilla preserving the tissue surrounding the implant using a 0.2 mm thick circular saw. Afterwards, the implants were cut lengthwise down the midline using low speed and plenty of irrigation to avoid overheating the sample, avoiding deterioration of the tissue that surrounded the implant (figure 5).

# *In vivo* biological evaluation of AVINENT dental implants



**Figure 5.** Section of a maxilla fragment.



**Figure 6.** Section of a sample included in plastic.

c) The sections were processed for study by electron microscopy, which includes controlled dehydration of the sample for fixation in resin (hydroxyethyl-methacrylate), a process that takes approximately 30 days. Later, a plastic capsule is obtained by photocuring, which is then covered with carbon, leaving the form ready to be submitted to morphological study. (fig. 6)

## **Histomorphometric Analysis**

The histomorphometric analysis was done by observing the images obtained by retrodispersed electrons. For histomorphometric scoring, we have analysed the calcified tissues in contact with the surface of the implant by analyzing the following parameters:

- *Presence of Osteoinduction Zones*  
Osteoinduction is defined as the formation of osseous tissue in non-calcified tissue zones, isolated or without contact with already formed bone, which can occur from different stimuli [1,2]. It is necessary to point out that the study of a two-dimensional image of the biological process of osseointegration can only reveal zones of apparent osseointegration.
- *Presence of Osteoconduction Zones*  
Osteoconduction is defined as the redirection in the growth of osseous tissue towards a determined zone, in this case the surface of the implant [1,2, 3]. It is explained by the ability of the biomaterial to direct the formation of new bone to the surface. This phenomenon can be observed with high reliability in this study technique.
- *Qualitative-quantitative analysis of the osseous spiral in contact with the surface of the implant*

Finally, we have completed an analysis table for each "active spiral" of osseous tissue that is found between two implant surface threads (Table 1). In order to include an active spiral in our analysis, it must originate from a bone trabeculum or from the bone cortex. Additiona-

lly, it must possess all of the elements indicated in Table 1, otherwise the analysis will not be applied but the characteristics of the bone tissue observed will be mentioned. The purpose is to obtain a qualitative and quantitative analysis of the bone tissue involved in the process of osseointegration. In the earlier application of this analysis, only the abbreviations shown in Table 1 were used. It is important to note that, as a consequence of the study technique, micro-separations may exist between the surface of the bone and the implant. Because of this, some allowances have been made in the quantities obtained from the filling and contact analyses observing the connection that exists between the surfaces. We have always rounded off the result obtained to the nearest 0 or 5.

CONTACT (C) AND FILLING(R)	TISSUES OBSERVED	EVALUATION	COMMENT
% C % R	Vascular Spaces (EV)	From (+) to (++++)	The presence of this element is vital in the initial stages of the formation of the bone. These spaces are progressively reduced by lamellar bone tissue [4, 5, 6]. The presence of Howship's lacunae in its borders indicates osteoclastic activity [7, 9].
	Controid Tissue (TC)	From (+) to (++++)	This tissue is formed in the initial stages of osseointegration. Its presence is an early sign of the process of membranous ossification [7, 8, 9].
	Fibroreticular Bone (HFr)	From (+) to (++++)	This bone tissue replaces the earlier tissue. In measuring the progress of bone maturation, it is replaced by lamellar bone tissue [10, 11].
	Lamellar Bone (Hla)	From (+) to (++++)	This tissue is deposited on the walls of vascular spaces. Afterwards, it makes up the osteonal remodeling that will form the Haversian system. [10,11].
	Osteonal remodeling (Os)	Presence (+) Absence (-)	It represents the tendency of the tissue to form Haversian systems. It is an indicator of the progress of bone maturation [10, 11, 12].

**Table 1.** Analysis applied to each active spiral of bone that is found in the study.

# *In vivo* biological evaluation of AVINENT dental implants

## RESULTS

### Histomorphometry

Of all the implants observed, the following examples of results obtained using secondary and retro dispersed electron microscopy are attached.

#### a) Histomorphometric analysis of an untreated implant and a treated implant with 45 days of intraosseous progression

##### Untreated Implant

Figure 7 shows the relationship between the implant and the surrounding tissue. No contact between the biomaterial and the bone tissue is observed in this section. Also absent is the typical deviation of the trabeculum towards the surface of the metal as is observed when osteoconduction zones are produced.

Figure 8 shows the distribution of the cancellous bone facing the surface of the implant (Ti). The distribution follows a straight line facing the surface of the implant without coming into contact with it.

##### Conclusion

Figures 7 and 8 show us that there is no osseointegration. The distribution of the bone tissue does not indicate an osteoconduction signal towards the surface of the implant.

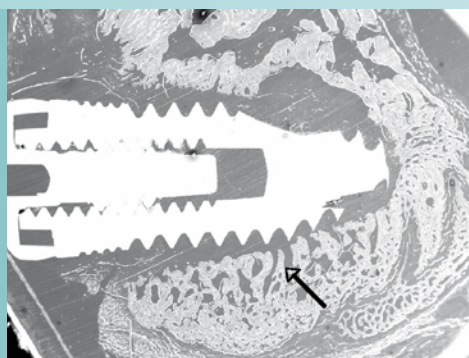


Figure 7

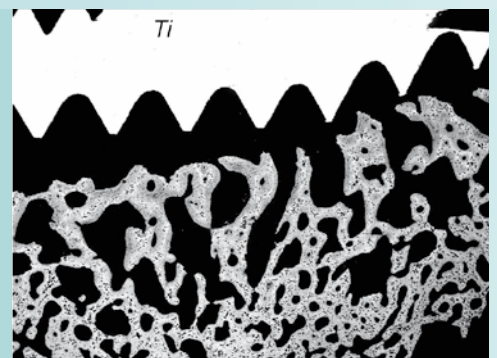


Figure 8




Figure 9

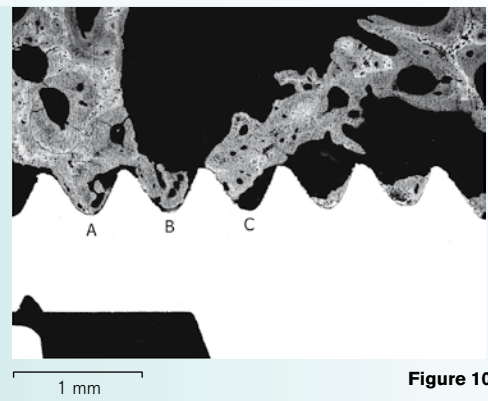


Figure 10

### Treated Implant

In figure 9 one is able to see multiple osteoconduction zones. The contact base that forms the bone extension (white arrows) with the surface of the implant is wider than the thickness of the bone trabeculae from which it arises.

Figure 10 shows 3 active spirals that arise from the cancellous bone that surrounds the implant. These are analysed in Tables 2, 3 and 4.

SPIRAL A (45 DAYS)			
% Contact (C) and Filling (R)	Tissues observed	Evaluation	
% C 50 % R 75	EV	+++	
	TC	+	
	HFr	++	
	HLa	+++	
	Os	-	

Table 2. Analysis of spiral A.

# In vivo biological evaluation of AVINENT dental implants

SPIRAL B (45 DAYS)		
% Contact (C) and Filling (R)	Tissues observed	Evaluation
% C 30 % R 65	EV	++++
	TC	+
	HFr	++
	HLa	+++
	Os	-




Table 3. Analysis of spiral B.

SPIRAL C (45 DAYS)		
% Contact (C) and Filling (R)	Tissues observed	Evaluation
% C 25 % R 45	EV	++++
	TC	+
	HFr	+
	HLa	+++
	Os	+

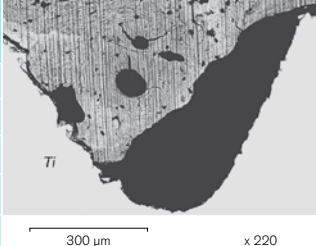


Table 4. Analysis of spiral C.

Figure 11 shows two active spirals that were analysed in Tables 5 and 6.

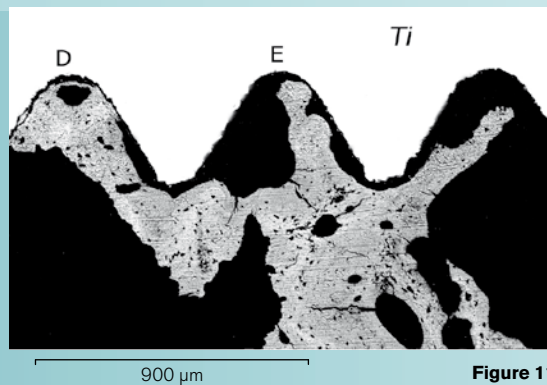




Figure 11

SPIRAL D (45 DAYS)		
% Contact (C) and Filling (R)	Tissues observed	Evaluation
% C 30 % R 50	EV	++++
	TC	-
	HFr	++
	HLa	+++
	Os	-



**Table 5.** Analysis of spiral D.

SPIRAL E (45 DAYS)		
% Contact (C) and Filling (R)	Tissues observed	Evaluation
% C 00 % R 30	EV	++++
	TC	-
	HFr	++
	HLa	+++
	Os	-



**Table 6.** Analysis of spiral E.

**Conclusion**

Various bone trabeculae have been observed directed towards the surface of the implant. The biomaterial has been inserted in an area of little bone tissue, nevertheless the high connection achieved between the bone tissue present and the bone tissue in contact with the implant can be seen on analysis. The spirals found show sufficient bone maturity.

# *In vivo* biological evaluation of AVINENT dental implants

## b) Histomorphometric analysis of an untreated implant and a treated implant with 90 days of intraosseous progression

### Untreated Implant

Figure 12 shows us the relationship between the implant and the adjacent structures. As can be seen in this section, the implant (Ti) is seen surrounded by bone tissue (H) and two dental elements (Ed) without coming into clear contact with either of them.




Figure 12

Figure 13 shows increases in different zones of the implant with the adjacent elements. One can confirm that the tissues do not come into contact with the implant.

### Conclusion

This implant was not osteointegrated according to the images. All the calcified tissues (bone, teeth elements) have organised around the biomaterial without coming into contact with it.

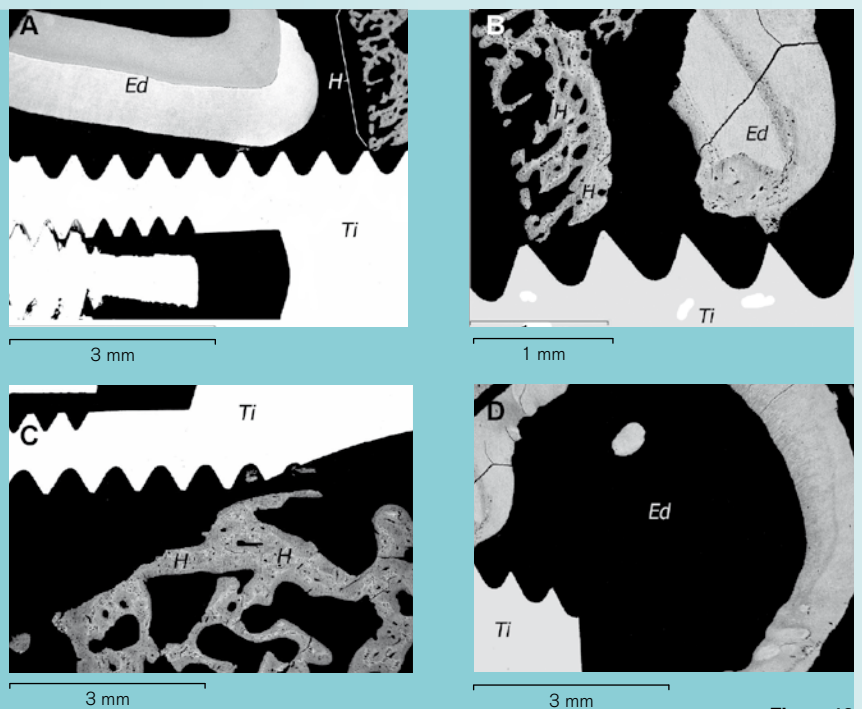


Figure 13

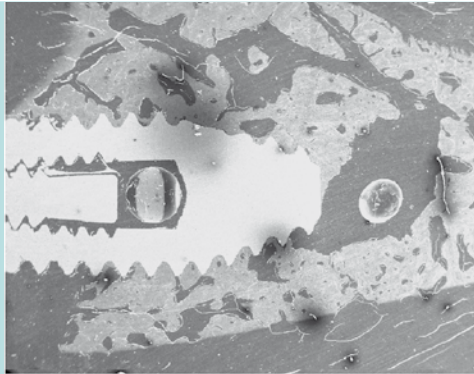


Figure 14

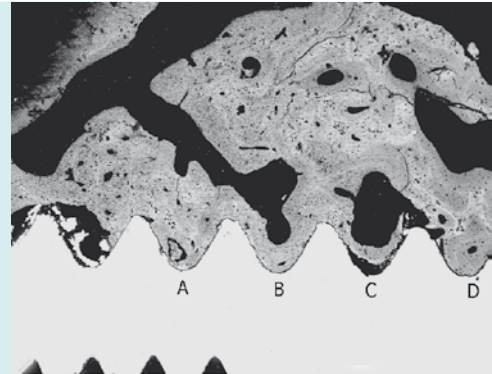


Figure 15

**Treated Implant**

Figure 14 shows the relationship between the implant and the tissue that surrounds it. One can observe an appreciable amount of active bone spirals intimately connected to the surface of the metal, which will be analysed below.

Figure 15 shows the upper active spirals observed in figure 14 labelled with the letters A, B, C and D, which will be analysed in Tables 7 and 11. Table 11 analyses spiral E, which cannot be seen in this image.

SPIRAL A (90 DAYS)		
% Contact (C) and Filling (R)	Tissues observed	Evaluation
% C 100 % R 90	EV	+
	TC	-
	HFr	+
	HLa	+++
	Os	+


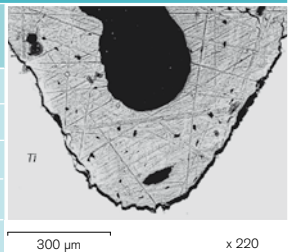


Table 7. Analysis of spiral A.


# In vivo biological evaluation of AVINENT dental implants

SPIRAL B (90 DAYS)		
% Contact (C) and Filling (R)	Tissues observed	Evaluation
% C 95 % R 85	EV	++
	TC	-
	HFr	+
	HLa	++++
	Os	-




**Table 8.** Analysis of spiral B.

SPIRAL C (90 DAYS)		
% Contact (C) and Filling (R)	Tissues observed	Evaluation
% C 20 % R 40	EV	++++
	TC	-
	HFr	+
	HLa	++++
	Os	-




**Table 9.** Analysis of spiral C.

SPIRAL D (90 DAYS)		
% Contact (C) and Filling (R)	Tissues observed	Evaluation
% C 90 % R 95	EV	+
	TC	-
	HFr	+
	HLa	++++
	Os	+

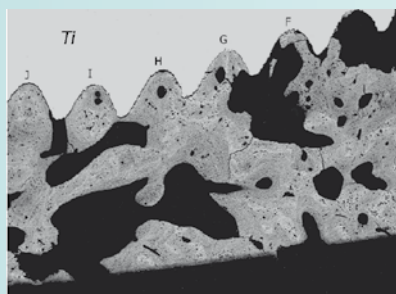


**Table 10.** Analysis of spiral D.

SPIRAL E (90 DAYS)		
% Contact (C) and Filling (R)	Tissues observed	Evaluation
% C 90 % R 95	EV	+
	TC	-
	HFr	+
	HLa	+++++
	Os	+



**Table 11.** Analysis of spiral E.

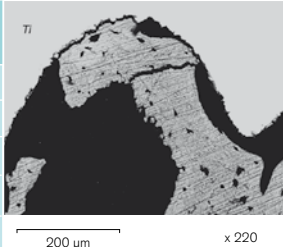


2 mm

**Figure 16**

Figure 16 shows the active spirals from the lower zone of the implant shown in figure 14. These are labelled with the letters F and J and are analysed in tables 12 and 17. Table 17 shows the analysis performed on spiral K that is not seen in this image.

SPIRAL F (90 DAYS)		
% Contact (C) and Filling (R)	Tissues observed	Evaluation
% C 33 % R 95	EV	+++++
	TC	-
	HFr	+
	HLa	+++
	Os	-



**Table 12.** Analysis of spiral F

# In vivo biological evaluation of AVINENT dental implants

SPIRAL G (90 DAYS)		
% Contact (C) and Filling (R)	Tissues observed	Evaluation
% C 100 % R 85	EV	++
	TC	-
	HFr	++
	HLa	+++
	Os	+

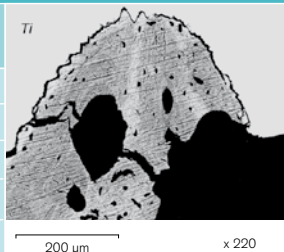


Table 13. Analysis of spiral G.

SPIRAL H (90 DAYS)		
% Contact (C) and Filling (R)	Tissues observed	Evaluation
% C 90 % R 95	EV	+
	TC	-
	HFr	+
	HLa	++++
	Os	+




Table 14. Analysis of spiral H.

SPIRAL I (90 DAYS)		
% Contact (C) and Filling (R)	Tissues observed	Evaluation
% C 100 % R 95	EV	+
	TC	-
	HFr	+
	HLa	++++
	Os	+






Table 15. Analysis of spiral I.

SPIRAL J (90 DAYS)		
% Contact (C) and Filling (R)	Tissues observed	Evaluation
% C 95 % R 95	EV	+
	TC	-
	HFr	+
	HLa	++++
	Os	+



**Table 16.** Analysis of spiral J.

SPIRAL K (90 DAYS)		
% Contact (C) and Filling (R)	Tissues observed	Evaluation
% C 60 % R 65	EV	+++
	TC	+
	HFr	+
	HLa	+++
	Os	-



**Table 17.** Analysis of spiral K.

### Conclusion

The implant-bone relationship achieved at 90 days is adequate. There is an increased number of active spirals with a level of maturity and bone quality that indicates an advanced state in the bone remodelling process. This can be fundamentally concluded thanks to the analysis of the different bone tissues that make up each active spiral. The big spaces without bone tissue observed in Figure 14 and in relation to the surface of the implant are compatible with the medullar/vascular spaces of the cancellous bone area.

# *In vivo* biological evaluation of AVINENT dental implants

## DISCUSSION AND CONCLUSIONS

### **Overall analysis of the active spirals in contact with the surface of the implant**

For the overall analysis in Table 18, the qualitative values (+), (++) , (+++) and (++++) were replaced by values of 1, 2, 3 and 4 respectively. Statistical software has been used to perform a quantitative analysis. In this manner, an average of the results can be established and the bone maturation process trend can be established.

The importance of the study lies in the appreciation of the grade of tissue maturity. According to our review, the spirals at 45 days demonstrate a lesser degree of bone maturity compared with the spirals at 90 days. This is a clear indication that there has been an adequate osseointegration process of the implant with the bone tissue that achieved contact with the surface of the biomaterial.

There is a clear difference in the osteoconductive capability of the BAS surface of the treated implant compared with the untreated implants analysed here. In the tissues that surrounded the untreated implants, neither active bone spirals nor reactions from the dental organ similar to those observed in the AVINENT implants were found.

ANALYSIS CRITERIA	RESULT 45 DAYS/90 DAYS	COMMENT
%C	16.87 / 69.65	Statistically significant differences exist in favour of the spirals with 90 days of osseointegration as related to contact (P-value = 0.0000131196).
%R	58.12 / 77.24	Statistically significant differences exist in favour of the spirals with 90 days of osseointegration as related to filling (P-value = 0.0116824)
EV	3.37 / 2.10	The most frequent score for spirals at 45 days was (++++). The most frequent score for spirals at 90 days was (++) . Comparison of the averages between both groups indicates a statistically significant difference (P-value = 0.00120435). This indicates a reduction in the vascular spaces in the matured active spirals.
TC	0.62 / 0.068	The result indicates that there is a greater presence of chondroid tissue in the samples at 45 days, with a statistically significant difference (P-value = 0.000146038). Therefore, the 90-day active spirals have progressed positively.
Hfr/HL	1.75/2.87/1.31/3.55	The relationship is always favourable towards HL, which indicates that this is the predominant calcified tissue as much in the 45-day samples as in the 90-day samples. Additionally, the 90-day samples have more HL, which indicates that the HFr tissue is being replaced. This is the natural tendency of maturing bone.
Os	12.5% / 65.5%	2.5% of the samples at 45 days showed osteons compared with 65% of the 1 samples at 90 days.

**Table 18.** Overall analysis of the study spirals.

# *In vivo* biological evaluation of AVINENT dental implants

## REFERENCES

[1] Albrektsson T, Johansson C. *Osteoinduction, osteoconduction and osseointegration*. Eur Spine J 2001;10 Suppl 2:S96-101.

[2] Dawidowicz A, Pielka S, Paluch D, Kuryszko J, Staniszewska-Kus J, Solski L. *Application of elemental microanalysis for estimation of osteoinduction and osteoconduction of hydroxyapatite bone implants*. Polim Med 2005;35(1):3-14.

[3] Lu X, Leng Y, Zhang X, Xu J, Qin L, Chan CW. *Comparative study of osteoconduction on micromachined and alkali-treated titanium alloy surfaces in vitro and in vivo*. Biomaterials 2005;26(14):1793-801.

[4] Carrillo JM, Sopena JJ, Rubio M, Redondo JI, Serra I, Soler C. *Experimental use of polyamide bands in combination with intramedullary pinning for repair of oblique femoral fractures in rabbits*. Vet Surg 2005; 34(4): 387-92.

[5] Dasso, G, Fernández, M. S. y Arias J. L. *Reparación ósea mediante aloimplantes sometidos a diferentes métodos de conservación en conejos*. Arch. med. vet 1998; 30(2): 57-66.

[6] Winet H, Albrektsson T. *Wound healing in the bone chamber: neovascularization during transition from the repair to the regenerative phase in the rabbit tibial cortex*. Int J Oral Maxillofac Implants 1988; 3(2): 99-107.

[7] Manzanares MC, Franch J, Carvalho P, Belmonte AM, Tusell J, Franch B, Fernandez JM, Cleries L, Morenza JL. *BS-SEM evaluation of the tissular interactions between cortical bone and calcium-phosphate covered titanium implants*. Bull Group Int Rech Sci Stomatol Odontol 2001; 43(3): 100-8.

[8] Goret-Nicaise M, Manzanares M.C, Nolmans E, Bulpa P, Dhem A. *Calcified tissues involved in the ontogenesis of the human cranial vault*. Anat Embryol 1988; 178: 399-406.

[9] Manzanares MC, Franch J, Carvalho P, Montesdeoca J, García J, Greco Y, Belmonte A, Delafuente M, Serra I. *The role of calcified tissues in the different stages of implant osteointegration*. Dent Med Probl 2004; 41(2): 179-191.

[10] Abrahamsson I, Berglundh T, Linder E, Lang NP, Lindhe J. *Early bone formation adjacent to rough and turned endosseous implant surfaces. An experimental study in the dog*. Clin Oral Implants Res 2004; 15(4): 381-92.

[11] Berglundh T, Abrahamsson I, Lang NP, Lindhe J. *De novo alveolar bone formation adjacent to endosseous implants*. Clin Oral Implants Res 2003; 14(3): 251-62.

[12] Franchi M, Orsini E, Trire A, Quaranta M, Martini D, Piccari GG, Ruggeri A, Ottani V. *Osteogenesis and morphology of the peri-implant bone facing dental implants*. ScientificWorldJournal. 2004; 4: 1083-95.

[13] Bosshardt. *Are Cementoblasts a Subpopulation of Osteoblasts or a Unique Phenotype?*. J Dent Res 2005; 84(5):390-406.